



Loscos-Arenas Jordi^{1*}, Tapia Gustavo², Moll-Udina Aina¹, Romanic Nevena¹ and Romera Pau¹

¹Department of Ophthalmology, Hospital Universitari Germans Trias i Pujol, Universitat Autònoma de Barcelona, Carretera de Canyet s/n, 08916 Badalona, Barcelona, Spain

²Department of Pathology, Hospital Universitari Germans Trias i Pujol, Universitat Autònoma de Barcelona, Carretera de Canyet s/n, 08916 Badalona, Barcelona, Spain

Dates: Received: 19 December, 2016; Accepted: 03 April, 2017; Published: 04 April, 2017

*Corresponding author: Loscos-Arenas Jordi, Hospital Universitari Germans Trias i Pujol, Department of Ophthalmology, Carretera de Canyet s/n, 08916 Badalona, Barcelona, Telephone: +34.93.465.12.00.00; E-mail: jordiloscos4@hotmail.com

Keywords: Cystic bleb; Collagen crosslinking; Riboflavin; Ki67 antibody

<https://www.peertechz.com>

Short Communication

Conjunctival Leaking Bleb after Cross-Linking using Riboflavin and UVA: A Histopathological Study

Abstract

Two conjunctival leaking blebs were excised to assess by histological methods the cellular effect after corneal cross-linking treatment. Sections were stained with hematoxylin-eosin and immunohistochemistry with the Ki67 antibody. The proliferating marker Ki67 was detected only in both treated pieces with a very significant increase in epithelial proliferating cells in one case but not in the other. Further studies are necessary to continue understanding the response to treatment of the ischemic blebs with CXL and riboflavin.

Introduction

Corneal collagen crosslinking (CXL), using ultraviolet-A (UVA) radiation and riboflavin, it is a non-invasive treatment of progressive keratoconus. As the procedure has shown a positive effect on the biomechanical of the cornea it could be a real alternative for late-onset bleb leakage in certain cases. Recent published studies [1,2], show encouraging results with this simple and non-invasive technique. Although in both series only one eye had a significant intraocular pressure (IOP) increase in the first set and two in the second, almost in all treated eyes the seidel test were normalized, which would support the postulate that CXL reinforces residual collagen bonding. However, in most of the eyes a slight IOP increase was observed and it is hardly attributable to the treatment because these eyes have a self-resolving tendency with a self-limiting seidel phenomena with fluctuating visual acuity.

Materials and Methods

To assess the cellular effect in the conjunctival leaking cystic blebs after corneal cross-linking treatment we have excised two cystic conjunctival blebs treated with MMC (0.02 mgr/mL for 2 minutes) of two eyes with a previous history of glaucoma surgery. The subjects gave their informed consent for the study. After excision, one piece of both ischemic tissues was treated with CXL and Riboflavin ex-vivo, keeping the other piece as a control. One Riboflavin drop (0.1% without dextran, Mediocross®M) was applied every 2 min for 20 minutes,

followed by UVA irradiation 9 mW/cm² - 10 minutes (CCL VarioSystem, Ophtec®). Samples were then fixed in formalin and embedded in paraffin, and sequential sections were stained with hematoxylin-eosin and immunohistochemistry with the Ki67 antibody.

Results

The hematoxylin-eosin (H&E) study did not show any significant difference between the treated piece with CXL and riboflavin and the untreated piece (Figure 1). The proliferating marker Ki67 was detected only in both treated pieces with a very significant increase in epithelial proliferating cells in one case but not in the other (Figure 2).

Discussion

Our findings can probably indicate proliferative cell variability and these results should be interpreted with caution because they are only two cases, but our observations point on Wollensak's [3], study of rabbits that finds the same distribution pattern in all treatment groups and controls. It could be as Wang [2], stated, that in the first case, the fibroblasts remainder that are present in the 75% of the leaking MMC treated blebs [4], and the growth-arrested cells, existing around the margin of the ischemic blebs were able to stimulate a fibrovascular repair, being responsible for the observed epithelial growth and makes the difference between those which will respond to treatment and those that will not. In addition, some indemnity of the basal cell layer underlying the Ki67 positive cells [3], could help the epithelial repair. We also have to consider that the epithelium wound healing process after the treatment

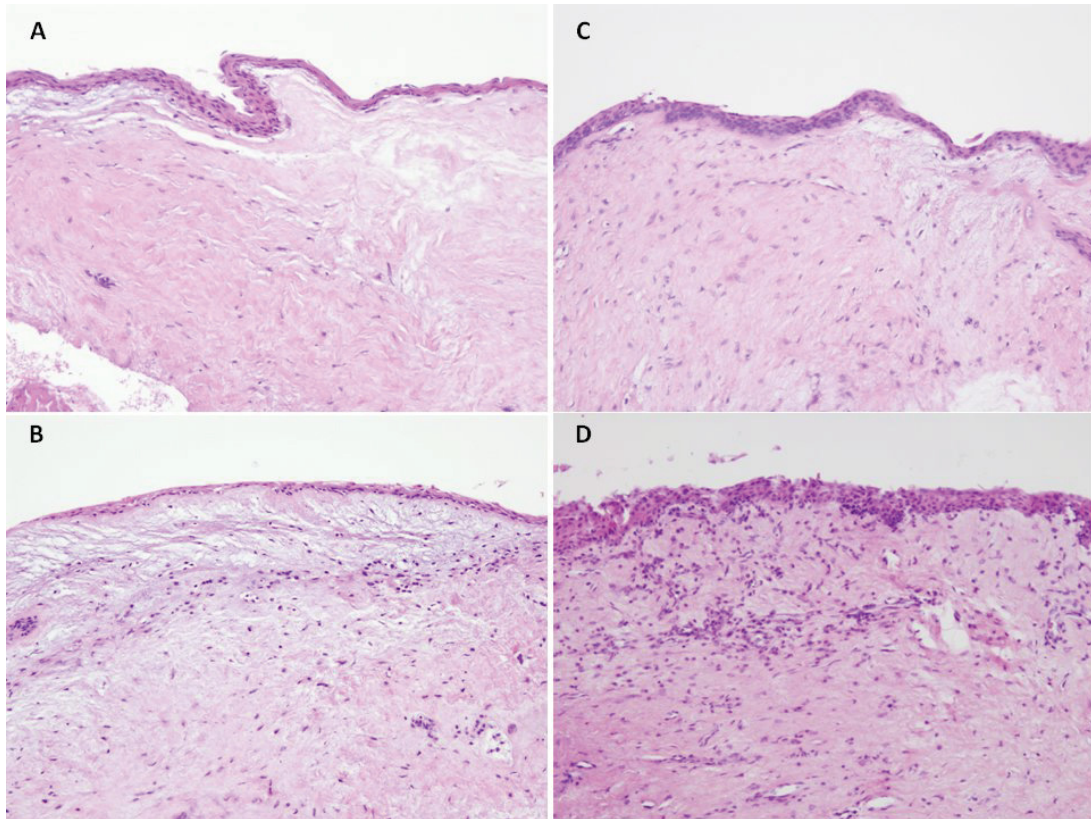


Figure 1: Histopathological features of conjunctival samples treated with CXL and Riboflavin (A and C) and untreated samples (B and D) were identical on hematoxylin-eosin stain (H&E) (x100).

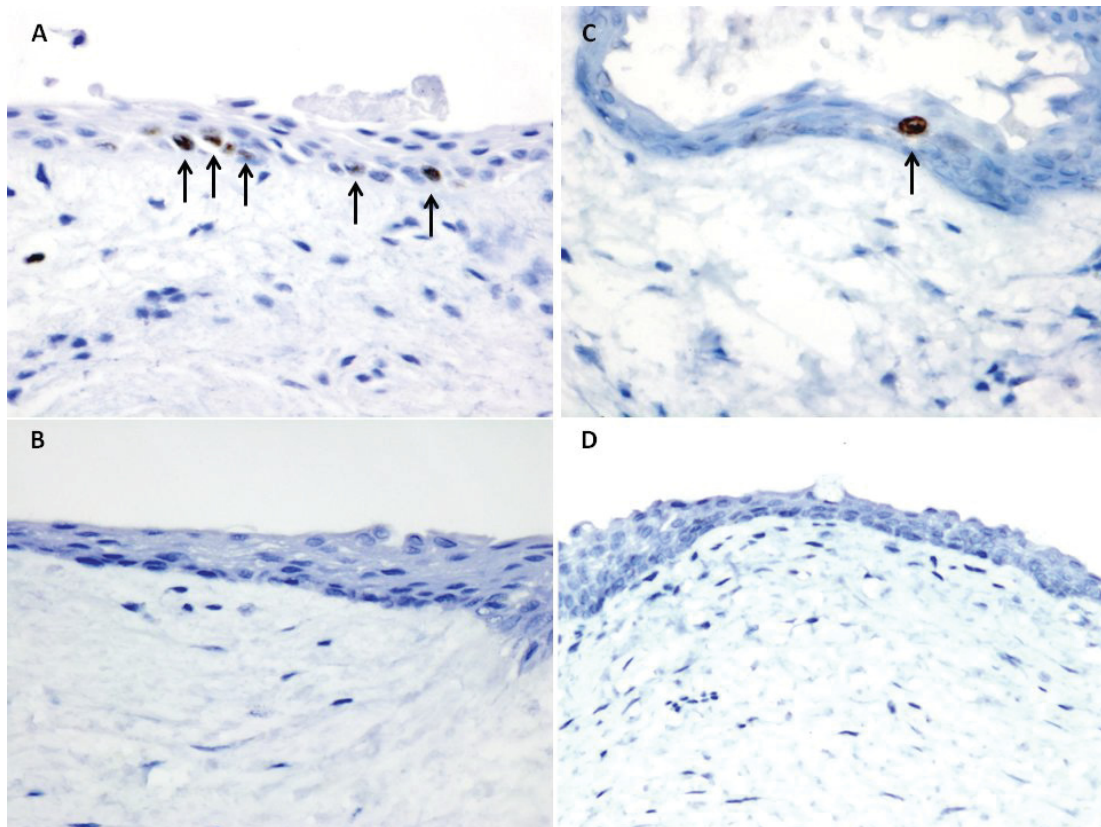


Figure 2: On Ki67 immunostains, only treated conjunctival samples showed Ki67 positive cells (A and C, arrow). A significant number of proliferating cells (Ki67 positive) can be seen in one case (A).

with CXL, UVA and Riboflavin could explain the response and add this restorative process to the hypothetical formation of covalent bonds among collagen fibres. We agree with Choy [1], that it could be a real alternative between conservative treatment and surgical procedures but further studies are necessary to continue understanding the response to treatment of the ischemic blebs with CXL and riboflavin which could be a simple alternative, economical, non-invasive and potentially repeatable.

References

1. Choy BN, Zhu MM, Shum JW, Ho WL, Chan JC, et al. (2016) Collagen

crosslinking in the management of leaking cystic blebs: a prospective study. *Graefes Arch Clin Exp Ophthalmol* 254: 529-533. [Link: https://goo.gl/8XKANa](https://goo.gl/8XKANa)

2. Wang Q, Harasymowycz P (2016) Collagen Cross-linking for Late-onset Bleb Leakage: 1-Year Results. *J Glaucoma* 25: e273-276. [Link: https://goo.gl/pSHiid](https://goo.gl/pSHiid)

3. Wollensak G, Mazzotta C, Kalinski T, Sel S (2011) Limbal and conjunctival epithelium after corneal cross-linking using riboflavin and UVA. *Cornea* 30: 1448-1454. [Link: https://goo.gl/bG4F2T](https://goo.gl/bG4F2T)

4. Elner VM, Newman-Casey PA, Patil AJ, Flint A, Biswas J, et al (2009) Aberrant wound-healing response in mitomycin C-treated leaking blebs: a histopathologic study. *Arch Ophthalmol* 127: 1036-1042. [Link: https://goo.gl/9afOcd](https://goo.gl/9afOcd)